


**PATIENT**

Mrs. O'Mally Christie

**PRESENTING CLINICAL SIGNS**

History: Historical grade 3/6 heart murmur. Recently coughing, getting tired on walks more quickly. Current medications: Vetmedin 1.25mg SID

**SPECIES**

Canine

**ECHOCARDIOGRAM FINDINGS**

2D, m-mode, color flow and doppler imaging is available. Diffuse thickening of mitral valve leaflets with mild prolapse into the left atrial lumen. Severe eccentric mitral regurgitation with severe left atrial dilation. LV dilation with adequate myocardial function. The tricuspid valve appears mildly thickened with mild tricuspid regurgitation. TR velocity is normal. Right heart is normal. The pulmonic and aortic valves are normal in morphology and mobility. Normal pulmonic and aortic outflow velocities. Mild aortic and no pulmonic insufficiency. No pericardial or pleural effusion noted. No obvious cardiac tumors observed.

**BREED**

Airdale Mix

**SEX**

Female Spayed

**CARDIAC CHART**
**AGE**

13 years

CANINE CARDIAC PARAMETERS	MR VMAX (m/s)	TR VMAX (m/s)	LA/AO (Boon method)	LA/AO (Heart Base; Swe)	FS (%)	EF (%)	EPSS (cm)
<b>NORMAL PARAMETER</b>	4.5-5.5	<2.7	1.3	<1.6	28-40	40-100	<0.6
<b>PATIENT</b>	5.0	2.5	1.7	2.2	44	76	0.4
CANINE CARDIAC PARAMETERS	HR (BPM)	AV VMAX (m/s)	PV MAX (m/s)	BODY WEIGHT (kg)	LA 2D short axis Base view (cm)	LVIDd Avg; 2D and m-mode short axis (cm)	LVIDs Avg; 2D and m-mode short axis (cm)
<b>NORMAL PARAMETER</b>	50-100	0.7-1.7	0.7-1.6	BELOW	BELOW	BELOW	BELOW
<b>PATIENT</b>	120	1.7	0.92	15.9	4.1	4.5	2.4
*Normal chamber parameters expressed as a mean value (SD)				3	1.27 (5.3)	2.46 (2.46)	1.36 (5.5)
BODY WEIGHT DEPENDENT PARAMETERS				5	1.40 (4.5)	2.74 (5.2)	1.60 (4.7)
<i>*Note: All measurements based upon multi-modal images and methods. An average value is reported.</i>				10	1.50 (3.8)	3.27 (3.5)	2.06 (3.1)
				15	1.83 (2.0)	3.71 (2.4)	2.43 (2.1)
				20	2.02 (1.9)	4.14 (2.2)	2.80 (2.0)
				25	2.18 (2.4)	4.48 (2.9)	3.10 (2.5)
				30	2.33 (3.3)	4.83 (3.9)	3.39 (3.4)
				35	2.48 (4.3)	5.17 (5.0)	3.69 (4.5)
				40	2.62 (5.2)	5.48 (6.1)	3.96 (5.4)
				50	2.88 (7.1)	6.07 (8.3)	4.46 (7.4)

**INTERPRETED BY**

 Maggie Machen Lamy,  
 DVM DACVIM  
 (Cardiology)

**IMAGING PERFORMED BY**

Kelly Reschny, RVT

**HOSPITAL NAME**

 Parkside Animal  
 Hospital

**REFERRING VET**

Dr. Zak

**INVOICE**

26095

**DATE**

8/30/22

**INTERPRETATION OF THE FINDINGS & FURTHER RECOMMENDATIONS**

The murmur is due to chronic degenerative valve disease causing severe mitral and mild tricuspid regurgitation. Significant left atrial and ventricular enlargement indicate the risk for spontaneous congestive heart failure is elevated. A small aortic leak is noted, and a baseline blood pressure is recommended. No obvious additional issues are noted.

A cough in this patient with severe heart disease is likely multi-factorial in origin, including mainstem bronchi compression and/or potentially some degree of upper or lower airway disease. Early CHF/pulmonary edema should also be considered; however, this is less likely based upon the reported history. Recommend institute cardiac supportive medications including a weak diuretic (spironolactone) and advise close monitoring at



**PATIENT**

Mrs. O'Mally Christie

home for need for Lasix therapy. Pending response, cough suppression (up to q4-6 hours) may also be helpful for mechanical cough. **Monitoring of sleeping breathing rates is recommended as the best way to screen for CHF at home.**

**SPECIES**

Canine

Omega fatty acid supplementation and mild salt restriction may also be of some long-term benefit. Monitor for development of a worsening cough, labored breathing, exercise intolerance or collapse episodes. Long term prognosis is guarded to poor, with an average survival time of 8-9mo for canine patients with active pulmonary edema on medications, however they generally are able to maintain a good quality of life for that period. Patient will always be at risk for recurrent CHF, development of arrhythmias/LA tear, syncope and/or sudden death in the future.

**BREED**

Airdale Mix

**SEX**

Female Spayed

**PLAN**

Dose increase: **administer Pimobendan 5mg PO q12h.** Institute Spironolactone 1-2mg/kg PO q12h. Baseline BP recommended. If >130mmHg, institute ACE-I (benazepril or enalapril) 0.5mg/kg PO q12h. Consider hydrocodone with homatropine for QOL (0.2-0.4mg/kg PO up to q4-6 hours PRN for cough; available in 5/1.5mg tabs and 5mg/5ml liquid suspension).

**AGE**

13 years

A renal panel is recommended in 1-2 weeks, then every 3-4 months lifelong.

**WEIGHT**

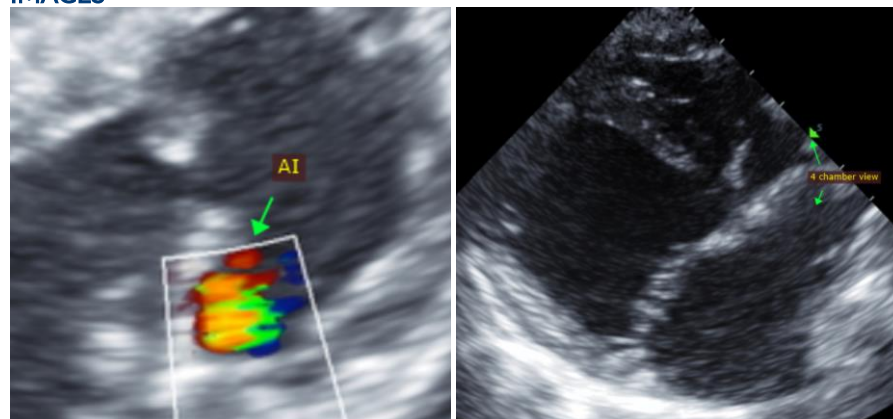
35.1lbs

A recheck echocardiogram is recommended in 6 months to screen for progression, sooner if clinical signs arise.

**INTERPRETED BY**

Maggie Machen Lamy,  
DVM DACVIM  
(Cardiology)

**IMAGES**



**IMAGING PERFORMED BY**

Kelly Reschny, RVT

**HOSPITAL NAME**

Parkside Animal  
Hospital

**REFERRING VET**

Dr. Zak

The information and recommendations provided are based on the images presented by the referring veterinarian. No evaluation can be communicated regarding pathology that was not visible in the image/video clips provided.

Thank you for this referral. This report was generated using transcription software, and minor dictation errors may be present. If the clinical or image interpretation does not parallel your findings or if I can be of any further assistance, please contact me.

**INVOICE**

26095

**DATE**

8/30/22

**Maggie Machen Lamy, DVM**  
Diplomate of the American College of Veterinary Internal Medicine (Cardiology)  
info@sonopath.com